

Est.  
1841

YORK  
ST JOHN  
UNIVERSITY

Jodzio, Krzysztof, Lojek, Emilia and Bryan, Karen ORCID logoORCID: <https://orcid.org/0000-0003-0742-1193> (2005) Functional and neuroanatomical analysis of extralinguistic disorders in right hemisphere-damaged patients. *Psychology of Language and Communication*, 9 (1). pp. 55-73.

Downloaded from: <https://ray.yorks.ac.uk/id/eprint/4416/>

The version presented here may differ from the published version or version of record. If you intend to cite from the work you are advised to consult the publisher's version:

[http://www.plc.psychologia.pl/plc/plc/contents/fulltext/09-1\\_3.pdf](http://www.plc.psychologia.pl/plc/plc/contents/fulltext/09-1_3.pdf)

Research at York St John (RaY) is an institutional repository. It supports the principles of open access by making the research outputs of the University available in digital form. Copyright of the items stored in RaY reside with the authors and/or other copyright owners. Users may access full text items free of charge, and may download a copy for private study or non-commercial research. For further reuse terms, see licence terms governing individual outputs. [Institutional Repository Policy Statement](#)

# RaY

Research at the University of York St John

For more information please contact RaY at [ray@yorks.ac.uk](mailto:ray@yorks.ac.uk)

KRZYSZTOF JODZIO

University of Gdańsk

EMILIA ŁOJEK

University of Warsaw

KAREN BRYAN

University of Surrey

FUNCTIONAL AND NEUROANATOMICAL ANALYSIS  
OF EXTRALINGUISTIC DISORDERS  
IN RIGHT HEMISPHERE-DAMAGED PATIENTS

The purpose of this article was to determine the prevalence of extralinguistic (non-aphasic) disorders, its clinical picture, and neuroanatomical correlates in right hemisphere – damaged patients. The cerebral perfusion pattern was determined by single-photon emission computed tomography (SPECT) in a group of 40 stroke patients with damage to the right hemisphere (RHD). The control group included 60 healthy subjects. The Polish version of the Right Hemisphere Language Battery (RHLB-PL) was used in the study. The group of RHD patients was not homogeneous with respect to character and severity of language disturbances. Some patients show very mild and selective linguistic disturbances, while others demonstrate more serious and generalized difficulties. The RHD patients, in comparison to healthy individuals, exhibited several communicative impairments, “apragmatic” in nature, including difficulties in performing tests assessing inferential reasoning, lexical-semantic processes, metaphor comprehension, and receptive prosody. Discourse ability seems to be particularly susceptible to damage since 95% of patients obtained abnormal scores for Discourse Analysis. Language disorders assessed by the RHLB-PL were associated with a variety of SPECT findings: language difficulties coexisted with perfusion defects within RH mostly involving the frontal cortex and thalamus.

Over the last few decades the language and communication impairments associated with right hemisphere damage (RHD) have been extensively studied in the field of neurolinguistics. Despite agreement that the left brain hemisphere (LH) is dominant for language processing, there are many studies showing that the deficits experienced by individuals following RHD may affect aspects of language (Beeman & Chiarrello, 1998). Moreover, studies using functional magnetic resonance imaging (fMRI) demonstrate that processing involved in language

production and comprehension occurs in diffuse brain regions. These regions include Broca's and Wernicke's areas, primary auditory and visual cortex, and frontal regions in the LH, as well as in the RH areas homologous to these regions (Binder et al., 1997; Bookheimer, 2002; Gernsbacher & Kaschak, 2003).

Specific deficits experienced by individuals following RHD are especially evident in the area of extralinguistic abilities, going beyond the "classic" (context-free, literal and componential) aspects of language processing: phonology, syntax and lexical-semantics. RHD individuals can have difficulties in processing complex features of language which are context bound and closely related to interpersonal communication. Possible consequences of RHD may include reduced discourse comprehension and production, communicative efficiency and specificity, capacity to process complex inferences, alternate and ambiguous meanings, sensitivity to contextual information, emotional tone, prosodic information, appreciation of shared knowledge and reflection (Myers, 1998, 2001).

Despite growing evidence on the relationship between the RH and extralinguistic skills, there is still little information on anatomical organization of these functions in the RH. According to one of the concepts introduced by Semmes (1968), the distribution of functions within the RH is less focal and its anatomical organization is more diffused in comparison to the LH. Results of clinical studies on RHD individuals strongly support that view, demonstrating that lesions in a given area of the RH may produce very different deficits, and that various lesion sites may result in the same deficit. However, it should be noted that many of the subjects in the literature on RHD communication deficits have had large lesions due to cerebral vascular accidents (CVA) with damage to more than one lobe of the RH (Myers, 1998; Tompkins, 1995).

More recent studies, mainly using functional brain imaging techniques, suggest rather different views on the anatomical/functional organization of the RH. They indicate that the LH and RH brain system is organized into a large number of relatively small but tightly clustered and interconnected modules with unique contributions to language processing. RH activity during language tasks appears analogous to the homologous LH regions: tasks that involve analyzing sensory input generally produce more posterior activity, and those that require making an active response or judgment, or generating a solution, give rise to frontal lobe activation (Bookheimer, 2002).

The processing of various aspects of the extralinguistic language system also appear to involve a distributed network of brain regions including extensive RH cortices. Robertson et al. (2000) showed that comprehension of narrative stories, compared with reading unrelated sentences, produced more neural activity in the right than LH of the frontal lobes. Processing of narrations increased RH activation in the precuneus, cuneus, posterior cingulate, parieto-temporo-occipital regions (bilaterally), the frontal poles, and a stretch of cortex extending along the right superior temporal sulcus to the right temporal pole. St George et al. (1999)

asked participants to read both titled and untitled stories. They found patterns of activation nearly identical to those reported by Robertson et al. (2000) and the activation was stronger when the stories were untitled. This indicates a special role of the RH regions in creating coherent narratives. Bottini et al. (1994) using positron emission tomography (PET) showed that comprehension of metaphors was associated with activation in several areas in the LH, but in addition, in the prefrontal cortex, the middle temporal gyrus, the precuneus and the posterior cingulate of the RH. Appreciating the moral of a story also requires activating a distributed set of brain regions which include the right temporal and right prefrontal cortices (Nichelli et al., 1995). Processing complex inferences (Goel & Dolan, 2000) and casual associative learning based on making inferences (Turner et al., 2004) are associated with activation in the right prefrontal cortex. Parsons and Osherson (2001) studied right and left brain systems for deductive versus probabilistic reasoning using PET. They demonstrated that deductive reasoning that accompanies inferencing activates mostly RH: areas near the right brain regions homologous to the left language of the middle temporal lobe, inferior frontal cortex, basal ganglia and right amygdala. Shammi and Stuss (1999) tested patients with focal brain damage in various areas of the brain looking for a specific brain region or a network that is especially relevant for humour appreciation and they found that the right frontal lobe is crucial for that human skill. Processing unusual semantic relationships (in generating unusual verbs) increased neural activation in right middle and right superior frontal gyri, left middle frontal gyrus and bilateral cerebellum. According to the authors of that study, these results support theories of RH involvement in the processing of distant associations that may be useful in creative thought and problem solving (Seger et al., 2000). Buchanan et al. (2000) examined the neural areas involved in the recognition of both emotional prosody (emotional tones included angry, happy, sad or neutral) and phonemic components of words used in spoken language using fMRI. They found that the detection of emotion, compared with verbal detection, resulted in significant activity in the right temporal and frontal lobes. However, Kotz et al. (2003) showed that positive and negative prosodic intonations can activate fronto-temporal areas in both hemispheres.

In this paper, we describe the results of a study on language disturbances after damage to the right cerebral hemisphere. Specifically, the present study examined three essential issues:

- extralinguistic processing in right hemisphere-damaged patients,
- neuroanatomical correlates of (non-aphasic) language disturbances after vascular damage to the right cerebral hemisphere,
- heterogeneity of language impairment in patients with different locations of lesion after right hemisphere stroke.

An attempt was made to link disorders of extralinguistic processing (e.g., inferential processing, comprehension of figurative meanings, and humour, etc.)

to the cerebral perfusion pattern determined by single-photon emission computed tomography (SPECT) in a group of patients with damage to the right hemisphere.

## **Method**

### **Participants**

A hundred participants were divided into two groups: clinical and control. The clinical group consisted of 40 patients (36 male, 4 female) who had incurred right-hemisphere ischaemic stroke. The cause of the stroke was large artery atherothromboembolism in all cases. The patients were between the ages of 20 and 71 years, with a mean of 54 years ( $SD = 11$ ), and had an average of 12 years of education ( $SD = 3$ ); all were right-handed and native speakers of Polish. Patients met the following selection criteria: (1) recent right-hemisphere stroke as determined by a clinical neurologist and computed tomography (CT) and/or MRI; (2) no history of cerebral disease or disorder prior to the stroke; (3) hearing adequate for completion of language tasks; and (4) no more than 30 days post-onset at the time of inclusion in the study (in days, mean 16,  $SD = 7$ , range 6-30). In addition, patients had no known history of other significant medical disease such as psychiatric disorder, progressive dementia, substance abuse, or additional neurological events (e.g., head injury). Fulfillment of these criteria was determined by interviewing the patient or, if necessary, a relative, and by reviewing the patient's medical record. All individuals were recruited consecutively from the Department of Neurology at the Medical University in Gdansk (Poland).

The control group included 60 healthy control subjects (49 male, 11 female), who had no history of CVA, dementia, or other neurological and psychiatric disorders. The subjects were between the ages of 45 and 74 years, with a mean of 53 years ( $SD = 6$ ), and had an average of 12 years of education ( $SD = 3$ ); all were right-handed and native speakers of Polish.

There were no significant group differences for age ( $t = 0.39$ ,  $p = 0.69$ ), years of education ( $t = -0.58$ ,  $p = 0.56$ ), and gender ( $\chi^2 = 0.16$ ,  $p = 0.4$ ).

The study was approved by the local ethics committee. Before testing, informed consent was obtained from each participant in the study. Each person was tested individually in a quiet testing room.

### **Language evaluation**

The Polish version of the Right Hemisphere Language Battery (RHLB-PL) was used in the study. Although, the general idea of the original RHLB tests (Bryan, 1995) was preserved, the content of almost all items was made appropriate for the Polish language (Łojek et al., 2000a,b).

The RHLB-PL is comprised of eight tests: Inferential Meaning, Lexical-Semantic, Written Metaphor, Picture Metaphor, Humour, Emotional Prosody, Linguistic Prosody and Discourse Analysis. There is a practice item for all tests.

The Inferential Meaning test consists of four short written paragraphs describing a situation or event. The examinee responds orally to four questions for each of the narrative, conversational, and emotional aspects of a text. The questions tap comprehension of information implicitly given in the passage.

The Lexical-Semantic test includes 13 high-frequency target nouns selected from a range of semantic categories, depicted by line drawings. For each word, drawings of five associated items are also presented, all in randomized order. These are: the target, two semantic co-ordinates, a functional associate, phonological and visual controls. The subject is asked to point to the picture representing the target item named by the examiner.

In the Humour test the participant must choose the correct punchline from 10 jokes. The responses include the correct punchline, a straight ending of neutral content (a concrete type of error) and a surprise ending that does not relate to the body of the joke (an abstract type of error). We also noted the number of inappropriate remarks and comments made by the subjects while performing the Inferential Meaning and Humour Tests.

Ten common metaphors are incorporated into short sentences printed on a card in the Written Metaphor test. Each sentence is followed by three randomized sentences representing possible meanings of the target: the correct metaphorical (the target), the literal (a concrete type of error) and the inappropriate meaning (another type of error). The examinee is asked to listen to the metaphorical sentence and then to point to the alternative that explains it. After making the choice, subjects are requested to give their own interpretation of the metaphor. The oral explanations can be classified as correct (adequate and abstract) or incorrect (too literal or inadequate). The list of possible correct and incorrect explanations has been obtained in a study on 80 healthy subjects (Łojek et al., 2000a,b).

A list of ten sentences, each containing a common metaphor, is presented in the Picture Metaphor test. A set of four pictures on a single plate is supplied for each sentence. Each set represents: the correct metaphorical meaning (the target), literal meaning (a concrete error) and two control pictures depicting one aspect of the sentence (other types of errors). The subject is asked to point to the picture that matches the meaning of the metaphorical sentence read by the experimenter. The accuracy of the subject's explanations of metaphors is also assessed.

The Prosody Test is based on the work by Pell (1996, 1997). The Production of Emphatic Stress from the original English RHLB was not appropriate for the Polish language. In the Polish version of the RHLB both prosody tests consist of 15 nonsense sentences recorded on a compact disk, read by a professional speaker. In the Emotional Prosody test sentences are read with three emotional tones: happy, sad or angry (in a random order). In the Linguistic Prosody test sentences are read

in random order with three linguistic intonations expressing a statement, a question or an order. In each of the prosody tests the subject is presented with a card with written names of the emotions or linguistic intonations. After listening to each sentence, the subject points to the word representing the emotional or linguistic tone of the sentence. There is a 5 second pause between each sentence. There are 4 practice items in each prosody test. After the examinee performs the practice items, the prosody tests are presented from the CD without stopping.

The Discourse Analysis evaluates two-way interaction or conversation. The examiner rates the patient's discourse on 15 rating scales: supportive routines (e.g., politeness), humour, questions (gaining information), assertive routines (e.g., making complain), narrative (e.g., length of utterances), variety of topic content, level of formality between participants, turn-taking, meshing (the timing of the interaction), discourse comprehension, prosodic ratings, organization of the output, completeness of discourse, eye contact and use of gestures. All the ratings use a 0-4 rating scale with 4 representing normal discourse skills and 0 a severely limited performance. The ratings are made with reference to a spontaneously occurring conversation and a recording of the greeting between examiner and patient at the beginning of a session when they are already acquainted, as well as during the session.

### **Cerebral blood flow SPECT imaging**

SPECT provides a reliable measure of regional cerebral blood flow and as such is instrumental in the identification of decreased flow that may be functionally relevant to cerebral changes and may not be detected by CT scanning and MRI. The method is increasingly used with the aim of improving diagnosis, selecting treatment or evaluating prognosis (Catafau et al., 1996; Jodzio et al., 2003).

Brain SPECT studies were performed 1 hour after the intravenous injection of  $^{99m}\text{Tc}$ -ECD (FAM, Łódź, Poland), mean activity 740 MBq (20 mCi). Scanning was performed on a triple-head gammacamera Multispect-3 (Siemens, Erlangen, Germany) using a low-energy, high-resolution collimator. The data were collected into a  $128 \times 128$  matrix, 4.8 mm per pixel. The raw data were smoothed with a Butterworth filter, cut-off frequency 0.35. Chang attenuation correction was not performed. The images were reoriented in the axial, coronal and sagittal planes. The data were displayed on a 10-grade colour scale. A radiology technician who was blind to the patients' diagnoses and neurological conditions read focal perfusion abnormalities. Regional cerebral blood flow on resting-state was assessed semi-quantitatively by calculating the index of regional mean counts/pixel values divided by those in the cerebellum.

Regions of interest (ROIs) covered frontal, temporal, parietal, occipital, thalamic and striatal areas, as well as for the whole left hemisphere and the whole right hemisphere. In total, there were an average of six regions (four cortical, two subcortical) for each hemisphere. ROIs were determined primarily using Catafau et al.'s (1996) method modified by Lass (1998). From the absolute flow values, because of

Table 1. Main results of the language tests for the clinical group and the normal controls group (between-group comparison)

TEST	GROUP		t-test value	p
	Clinical RHD* (n = 40) Mean (SD)	Control Healthy individuals (n = 60) Mean (SD)		
Inferential Meaning	11.67 (3.04)	14.56 (1.29)	-5.66	0.001
Lexical-Semantic	11.25 (1.97)	12.75 (0.65)	-4.65	0.001
Humour	7.62 (2.51)	8.12 (2.24)	-1.02	0.308
Metaphor Picture	6.15 (2.50)	7.85 (2.47)	-3.32	0.001
Metaphor Written	8.16 (2.42)	9.27 (1.10)	-2.65	0.01
Linguistic Prosody	10.22 (3.68)	13.20 (2.49)	-4.48	0.001
Emotional Prosody	10.30 (3.47)	13.45 (2.63)	-5.14	0.001
Discourse	42.47 (11.56)	59.15 (1.87)	-9.05	0.001

\* RHD - right hemisphere-damaged subjects

the important inter-subject variability and small sample size, we derived for each region of interest an Asymmetry Index (AI) using the following formula:

$$AI = \frac{2(L - R)}{L + R} \times 100\%$$

The letters 'R' and 'L' are mean counts/pixel values in the right and left hemisphere, respectively. Perfusion deficits with asymmetry index value exceeding 10 percentage were considered to be significant, which was two standard deviations (SD) above the mean for the control group of healthy age-matched volunteers (Lass, 1998). Therefore, the Asymmetry Index (the right-to-left ratio) reflects the severity of the right hemisphere hypoperfusion (with greater AI indicating larger areas of damage within the right hemisphere). During the recordings, the subjects were lying in a quiet dimly lit room with eyes closed and ears unplugged. The interval between SPECT and assessment of language functioning did not exceed three days.

## Results

### Overall description of extralinguistic processing in RH stroke patients (group means)

Table 1 presents the mean scores of the clinical and control groups on each test in the RHLB-PL battery. We compared the scores of both groups using Student's *t*-test. The clinical group (i.e., RHD patients) performed worse on most of the tests. Between-group difference were only found for the Humour test ( $p = 0.308$ ).



Figure 1. Histograms demonstrating the patterns of performance of the RHLB-PL battery in the groups. Chi-square comparisons were performed separately for each language test:

1 – the Inferential Meaning ( $\text{Chi}^2 = 19.53, p < 0.001$ );

2 – the Lexical-Semantic ( $\text{Chi}^2 = 47.99, p < 0.001$ );

3 – the Humour ( $\text{Chi}^2 = 0.91, p = 0.339$ );

4 – the Picture Metaphor ( $\text{Chi}^2 = 6.59, p < 0.01$ );

5 – the Written Metaphor ( $\text{Chi}^2 = 5.82, p < 0.01$ );

6 – the Linguistic Prosody ( $\text{Chi}^2 = 15.66, p < 0.001$ );

7 – the Emotional Prosody ( $\text{Chi}^2 = 9.25, p < 0.01$ );

8 – Discourse ( $\text{Chi}^2 = 61.66, p < 0.001$ );

RHLB-PL – Right Hemisphere Language Battery (Polish adaptation);

CTR – Control group (Healthy individuals,  $N = 60$ );

RHD – Clinical group (right hemisphere-damaged patients,  $N = 40$ )

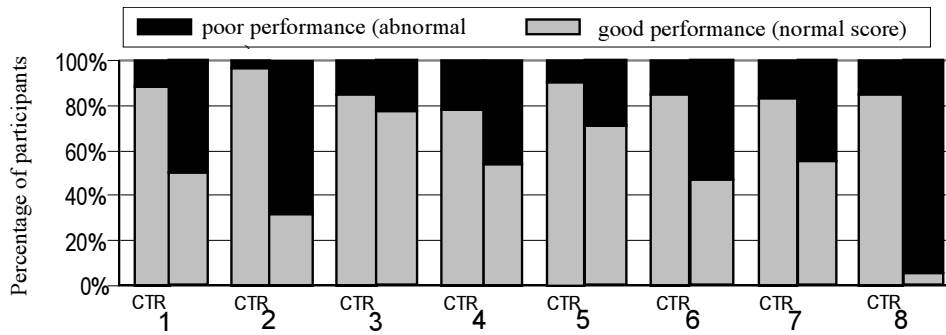


Figure 2. Two main effects of the test and the group in relation to the metaphor tests scores

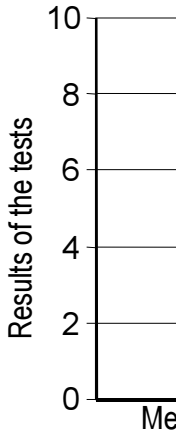
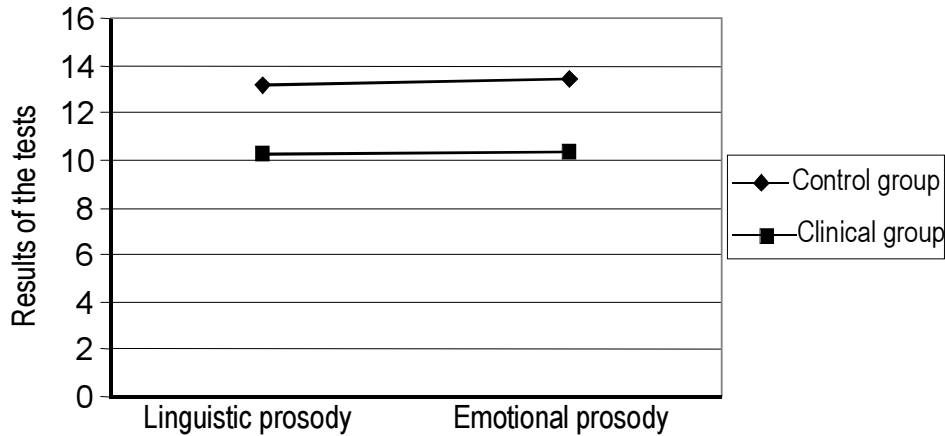


Figure 3. Main effect of the group in relation to the prosody tests scores



On the basis of means and standard deviations computed for the control group, we divided the subjects into two groups according to their performance on the language tests. Scores corresponding one standard deviation below the mean were considered impaired (abnormal). Thus, scores on each test separately were classified into a dichotomy (“intact” versus “impaired”) as reflected by the ratio of patients’ percentages. Then, between-group chi-square comparisons were performed. Histograms illustrating results of this analysis and patterns of performance are presented in Figure 1. Similarly to the analysis using the *t*-test, the two groups differed on most of the language tests, except the Humour test. 77% of the RHD patients did this test correctly, like the healthy subjects (85%) ( $\text{Chi}^2 = 0.91$ ,  $p = 0.339$ ). In contrast, results of discourse evaluation revealed highly significant between-group differences, with the discourse of only 5% of RHD patients (2 patients) being classified as “intact”, while in the control group 85% performed the test without any problem ( $\text{Chi}^2 = 61.66$ ,  $p < 0.001$ ).

We analyzed hypothetical effects of performance on two pairs of the tests: Metaphor and Prosody. For this purpose, one within-subject (Type of the test: Picture versus Written, or Linguistic versus Emotional) and one between-group (Clinical versus Control) repeated measures ANOVA (analysis of variance) was conducted for averages on the Metaphor tests and separately for averages on the Prosody tests. On the metaphor tests, the main effect of the test was found indicating better performance on picture than written condition. The main effect of the group was also significant, with worse performance in the clinical group [ $F(1;97) = 12.69$ ,  $p < 0.001$ ]. On the prosody tests, a main effect of the group was also present, favoring control (healthy) subjects, regardless of type of the Prosody test [ $F(1;97) = 33.91$ ,  $p < 0.001$ ] (Figures 2 and 3).

Table 2. Pearson coefficient correlations between the results on the RHLB-PL tests and brain SPECT parameters (Asymmetry Indexes) in RHD patients (N = 40)

LOC	LANGUAGE TEST								Total score (sum)
	Inferential meaning	Lexical -semantic	Humour	Metaphor picture	Metaphor written	Linguistic prosody	Emotional prosody	Discourse	
FR	- 0.54***	- 0.39**	-	- 0.36*	-	-	-	- 0.35*	- 0.39*
TE	-	-	-	-	-	-	-	- 0.36*	-
PA	-	- 0.41**	-	- 0.32*	-	-	-	- 0.43**	- 0.38**
OC	-	-	-	-	-	-	-	-	-
ST	-	- 0.34*	-	-	-	-	- 0.36*	- 0.41**	- 0.36*
TH	- 0.35*	-	-	- 0.32*	-	-	- 0.31*	- 0.49***	- 0.38*
ME	-	- 0.37*	-	-	-	-	- 0.37*	- 0.42**	- 0.39*

Only significant correlations are shown; \*  $p < 0.05$ ; \*\*  $p < 0.01$ ; \*\*\*  $p < 0.001$

Higher Asymmetry Index of cerebral hypoperfusion (decreased blood flow in the right hemisphere) means worse performance on the language test (lower score)

SPECT – location of cerebral blood flow assessed by single-photon emission computed tomography

FR – frontal cortex

TE – temporal cortex

PA – parietal cortex

OC – occipital cortex

ST – striatum

TH – thalamus

ME – mean hemispheric blood flow

### **Neuroanatomical correlates of language disturbances in the light of brain SPECT findings**

We studied correlations between disorders of particular language functions and disorders of cerebral blood flow. In the SPECT studies, the incidence of perfusion abnormalities was determined for each anatomical region and the relationship between these abnormalities and various language disturbances (measured by the RHLB-PL) was tested for statistical significance using Pearson correlations analysis (Table 2).

According to Table 2, right-frontal cortex damage related significantly to performance in several tests, including Inferential Meaning, Lexical-Semantic, Metaphor Picture, and Discourse Analysis. In other words, cerebral dysfunction of the right frontal cortex appeared to be associated with particular language deficits. The performance on Metaphor Picture was associated with right-parietal cortex and right thalamus as well. Thus, the influence of the size and locus of the right brain lesion on patients' performance on language tests is evident. No significant correlations were noted between blood flow in occipital cortex and all the RHLB-PL tests, as well as between any of the SPECT dimensions and Humour, Metaphor Written and Linguistic Prosody tests.

### **Heterogeneity of language impairment in patients with different location of the right-hemisphere stroke**

In order to determine the heterogeneity of language impairments in the light of neuroanatomical SPECT findings, the relationship between these two aspects of language disturbances (i.e., functional versus structural) was examined to determine the incidence of language impairment as a function of lesion site (Table 3).

Perfusion deficits with Asymmetry Index values exceeding 10% in SPECT examination were considered to be significant (Jodzio et al., 2003; Lass, 1998). We used the six cerebral regions of interest to divide the clinical group (RHD patients) into a particular 'neuroanatomical' subgroup based on SPECT findings. Then we calculated the number of patients in each subgroup who were classified as either "normal" or "impaired" on any one particular language test (Good versus Poor performances). If most (over 70%) of patients in the particular 'neuroanatomical' subgroup were impaired on the language test, an asymmetry (i.e., patients' proportion) was considered significant.

As shown in Table 3, very similar patterns of language test performance were found in subgroups 1, 3, and 6 (40% of all RHD subjects). Most of these patients (83-100%) were impaired on discourse only. The right hemisphere damage involved solely frontal cortex or subcortical structures, or a very mild generalized deficit of cerebral blood flow.

Another common pattern of test performance involved subgroups 2 and 5 (47.5% of all RHD subjects). Most of these patients (83-100%) obtained poor

Table 3. Percentage of RHD patients with specific language impairment (distinct patterns of RHLB-PL performance) as a function of lesion location

Shaded areas represent cases of disproportion of the language test scores with significant advantage (over 70% of patients) of poor performance (I) over correct (+) performance

\* Lesion location within right hemisphere was determined by cerebral blood flow single-photon emission computed tomography SPECT parameters: VeM – very mild generalized deficit of cerebral blood flow with Asymmetry Index not exceeding 10%; AnC – anterior part of the cortex, including frontal lobe; PoC – posterior part of the cortex, including parietal, temporal and occipital lobes; Su – subcortical structures, including striatum and thalamus

Sub-group	Lesion location
1. n=6	VeM
2. n=11	AnC + S
3. n=6	Su
4. n=3	PoC + S
5. n=8	AnC + P
6. n=4	AnC
7. n=2	PoC

Table 4. The performance of heterogeneous right hemisphere damaged groups (A, B, C) and control group on the RHLB-PL

Test	Group A Mean (SD)	Group B Mean (SD)	Group C Mean (SD)	Controls Mean (SD)	F ANOVA	p
1	13.06 (2.38)a	9.74 (2.64)b	14.60 (1.14)a	14.56 (1.29)a	34.80	0.001
2	12.50 (0.63)a	10.37 (2.34)b	10.60 (1.14)b	12.75 (0.65)a	22.75	0.001
3	9.00 (1.26)a	6.58 (2.57)b	7.20 (3.56)ab	8.12 (2.24)ab	3.77	0.05
3a	0.25 (0.45)a	1.47 (1.81)b	1.20 (1.64)ab	0.58 (1.03)a	3.99	0.01
4	7.31 (2.39)ab	5.16 (2.41)a	6.25 (1.50)ab	7.85 (2.47)b	6.17	0.001
4a	1.81 (1.87)ab	2.84 (1.74)a	2.25 (1.71)ab	1.57 (1.77)b	2.54	0.05
4b	0.81 (1.05)a	1.95 (1.68)b	1.50 (0.58)ab	0.58 (1.01)a	6.97	0.001
4c	7.69 (1.30)a	6.63 (1.61)a	7.50 (1.29)a	9.50 (1.10)b	30.05	0.001
5	9.62 (0.62)a	7.22 (2.53)b	6.50 (3.70)b	9.27 (1.10)a	12.36	0.001
5a	0.06 (0.25)a	1.22 (1.86)b	2.25 (2.87)b	0.27 (0.76)a	7.39	0.001
5b	0.31 (0.60)a	1.50 (1.29)b	1.25 (0.96)ab	0.45 (0.79)a	7.95	0.001
5c	7.94 (1.57)a	7.06 (2.07)a	6.00 (1.15)a	9.02 (1.35)b	11.58	0.001
6	12.62 (3.07)a	8.26 (2.82)b	10.00 (4.36)ab	13.20 (2.49)a	16.56	0.001
7	11.75 (1.57)ab	9.00 (4.11)a	10.60 (3.97)ab	13.45 (2.63)b	11.96	0.001
8	49.25 (5.63)a	36.53 (11.93)b	43.40 (13.81)b	59.15 (1.87)c	64.60	0.001
9	1.25 (0.93)a	1.16 (1.21)a	0.60 (1.34)ab	0.52 (0.93)b	3.45	0.05

Groups A, B and C – RHD subjects (A – anterior or subcortical lesions, B – anterior, posterior and subcortical lesions, C – posterior and/or subcortical lesions). Test: 1 – Inferential Meaning (correct responses), 2 – Lexical–Semantic (correct responses), 3 – Humour (correct responses), 3 a – Abstract errors on Humour, 4 – Metaphor Picture (correct responses), 4 a – Concrete errors on Metaphor Picture, 4 b – Other types of errors on Metaphor Picture, 4 c – Correct explanations of metaphors on Metaphor Picture, 5 – Metaphor Written (correct responses), 5 a – Concrete errors on Metaphor Written, 5 b – Other types of errors on Metaphor Written, 5 c – Correct explanations of metaphors on Metaphor Written, 6 – Linguistic Prosody (correct responses), 7 – Emotional Prosody (correct responses), 8 – Discourse, 9 – Inappropriate remarks and comments

results on several tests, such as Inferential Meaning, Lexical-Semantic, Linguistic Prosody, and Discourse. These patients had larger cerebral changes compared to the previous subgroups, with the lesion extending temporo-parietally and involving more of the deep-brain structures, including striatum and thalamus.

The last specific pattern of language difficulties was typical for individuals in subgroups 4 and 7 (12.5% of all RHD subjects) who manifested selective deficits of lexical-semantic abilities and discourse. These subjects' brain lesions were classified on the basis of SPECT scans as predominantly posterior or subcortico-posterior.

Because the small sample of patients in each subgroup did not permit any statistical analysis to be done, we classified these seven subgroups of patients to form three larger groups based on their patterns of language impairment described above. The groups were labeled consecutively A, B, and C. The group A (n = 16) consists of patients who originally formed the subgroups 1, 3 and 6, the group B

( $n = 19$ ) consists of patients in the subgroups 2 and 5, and the group C ( $n = 5$ ) consists of patients in the subgroups 4 and 7 (see table 3). There were no differences between groups A, B, C and the control subjects on age ( $F = 0.09$ ,  $p = 0.964$ ) and the number of years of education ( $F = 1.69$ ,  $p = 0.17$ ). Next, most extensive analysis of heterogeneity of language impairment in groups A, B and C was performed. Table 4 shows the performance of group A, B and C subjects on the main tests of the RHLB-PI as well as specific errors made by them while completing some of the tests. Means sharing 'a' subscript, means sharing 'b' subscript, and means sharing 'c' subscript do not differ significantly at  $p < 0.05$  (Tukey's multiple range test).

As table 4 shows, the most extensive disorders were present in the group B subjects with anterior, posterior and subcortical lesions of the RH. Their results were significantly lower than those of the controls on all RHLB-PI tests, including Humour, as far as the number of abstract errors was concerned. These subjects also made significantly more errors on both Metaphor tests as well as inappropriate remarks and comments than the controls. Moreover, the scores obtained by group B on most of the RHLB-PI tests significantly differed from those obtained by RHD patients in group A.

The performance of the group C subjects with posterior and/or subcortical lesions in the RH was markedly impaired on three tests compared with the healthy controls and group A: Lexical-Semantic, Metaphor Written (including significantly high number of concrete errors) and Discourse Analysis.

The group A subjects with anterior or subcortical lesions showed significant problems with social communication as assessed on the Discourse Analysis test. These patients also made a lot of inappropriate remarks and comments, significantly more than the healthy subjects.

## Discussion

The results of our research confirm the previously described problems of RHD patients in the area of extralinguistic processing (Myers, 2001; Ulatowska et al., 2003). The RHD patients, in comparison to healthy individuals, exhibited several communicative impairments, "apragmatic" in nature. As a group, these patients displayed difficulties in performing tests assessing inferential reasoning, lexical-semantic processes, metaphor comprehension, receptive prosody, and discourse. Discourse ability seems to be particularly susceptible to damage since 95% of patients (Figure 1) obtained abnormal scores for Discourse Analysis. Even 5 out of 6 patients with very mild deficit of cerebral blood flow had poor discourse (see Table 3, subgroup 1). Indeed, it is now a well-established finding in the more recent literature that the RH makes unique contributions to keeping track of the topic, drawing inferences in conversation, and integrating meta-linguistic information into a complete representation of meaning and intent, aspects of language

that are critical to social communication. Typically, RHD patients show difficulty making inference revisions from ambiguous or complex material, deficits in apprehending main themes, digressive, inefficient narratives, problems with topic maintenance, low sensitivity to paralinguistic information transmitted by facial expression or gestures (Myers, 2001). When conversing, these patients tend to focus on details, interject inappropriate remarks and commentary, and omit the most important information.

Interestingly, we did not find a between-group difference for the measures of performance on the Humour test. This might be rather surprising if one expected that humour comprehension is considered to be highly sensitive to RH lesions (Łojek et al., 2000b), but Bryan and Hale (2001) suggest that language used on the Humour test is very complex in nature, therefore this test may not be as effective as other RHLB subtests in neuropsychological diagnosis. In addition, the humour on this test is confounded by cultural and personal characteristics, which may not make this test an ideal candidate for language screening.

Results of the present research demonstrate that RHD patients, as a group, suffer from deficits in metaphorical comprehension. They tend to choose literal interpretations of the metaphors. The deficits were evident for both verbal (sentences) and visual (pictures) conditions that required selecting correct answers from alternatives. Our results are relevant to the data reported by other researchers (Bryan, 1995; Rinaldi et al., 2004; Ulatowska et al., 2003; Van Lancker, 1990). Nevertheless, the deficit in metaphorical comprehension was not indiscriminate but strongly dependent on the type of material which is processed. Our findings are somewhat inconsistent with a study by Rinaldi et al. (2004), who found a dissociation of metaphor comprehension in RHD patients with verbal (sentences) and visual (pictures) material: RHD patients performed more poorly in the later than in the former condition. Instead, it seems likely from our data that verbal (written) metaphors are significantly more difficult for interpretation than picture metaphors. The reason for our result may be the level of difficulty of the written metaphor test in the Polish version of the RHLB-PL, since that test was also more difficult for the controls.

Neuroanatomical correlates of language disturbances after RH stroke are complex. Language disorders assessed by the RHLB-PL were associated with a variety of SPECT findings: language measurements correlated well with perfusion abnormalities in both cortical and subcortical areas. For example, difficulties in inferential meaning (i.e., comprehending language in context which requires making inferences) coexisted with perfusion defects within RH involving the frontal cortex and thalamus, while discourse-related disturbances could be attributed to many different locations of lesion, except for the occipital cortex. Although the deficits in making inferences in RHD patients have been documented very well, some authors argue (Ferstl et al., 2002) that certain behaviors are typical for patients with frontal lesion regardless of its lateralization. In particular, patients with



prefrontal brain damage, either left- or right-sided brain injury, often fail to take into account the communicative context and fail to comprehend implicit information. Two main reasons for this discrepancy have been proposed. The first issue concerns the patient selection, while the second one concerns the selection of material and comprehension tasks.

A striking observation in our patients was lack of specific brain SPECT correlations with metaphor written (verbal) comprehension. On comparison, metaphor picture comprehension could be attributed to lesions restricted to the frontal and parietal cortex, as well as the thalamus. Similarly, specific SPECT correlation was found only for emotional but not for linguistic prosody (Table 2). This would be consistent with the theoretical position that cerebral organization of some language functions attributed to the RH (e.g., discourse) seems to be diffuse and non-specific in nature, while other language functions (e.g., inferential meaning, metaphor picture) are more focally distributed within the RH. In considering the possible neuroanatomical origins of language deficits after RH stroke, our impression may be that such deficits were attributable to defects of large anatomo-functional loops rather than lesions restricted to particular brain areas. This gives credibility, at least in this instance, to the view that these loops consist of cortico-striato-thalamo-cortical pathways which serve to transfer information between different (cortical and subcortical) structures. A similar view regarding the cerebral aspect of language functioning is adopted by aphasiologists concentrating on language consequences of left (dominant) hemisphere damage (Jodzio et al., 2003).

Lack of significant correlations between linguistic prosody and cerebral blood flow in any of the right hemisphere brain regions may suggest that the left hemisphere was more involved in the tasks requiring linguistic processing. A significant relationship between the mean hemispheric blood flow in the right hemisphere and the performance on the second part of the prosody test confirms the important role of the right hemisphere in processing the emotional aspects of prosody. The above results are concordant with other studies on prosody in brain damaged patients (Karow et al., 2001; Pell & Baum, 1997). Our data also show the important role of subcortical structures in comprehending prosodic information. Patients with cortical-subcortical lesions to the right hemisphere showed the most severe linguistic and emotional prosodic deficits. There were also significant correlations between the parameters on the blood flow in right subcortical structures and the performance on the Emotional Prosody test. These observations are congruent with the study by Karow et al. (2001) demonstrating that the presence of right cortical-subcortical lesions is crucial for the impairment of affective prosody processing. Subjects with cortical damage only, regardless of side of lesion (left or right), can perform without significant difficulty on prosody tests.

The group of RHD patients is not homogeneous with respect to character and severity of language disturbances. On the contrary, heterogeneity of language impairment after RH stroke is evident (Table 3). Similar results have been ob-

tained by Ulatowska et al. (2003), who also noted that some patients show very mild and selective linguistic disturbances (concerning mainly discourse), while others demonstrate more serious and generalized difficulties.

### Acknowledgments

The authors are grateful to Dr. Dariusz Gąsecki and Prof. Piotr Lass from the Departments of Neurology and Nuclear Medicine at the Medical University in Gdańsk for their help and comments.

### References

- Beeman, M., & Chiarrello, C. (Eds.) (1998). *Right hemisphere language comprehension. Perspectives from cognitive neuroscience*. Mahwah: LEA.
- Binder, J.R., Frost, J.A., Hammeke, T.A., Cox, R.W., Rao, S.M., & Prieto, T. (1997). Human brain language areas identified by functional magnetic resonance imaging. *Journal of Neuroscience*, 17, 353-362.
- Bookheimer, S. (2002). Functional MRI of language: new approaches to understanding the cortical organization of semantic processing. *Annual Review of Neuroscience*, 25, 151-188.
- Bottini, G., Corcoran, R., Sterzi, R., Paulesu, E., Schenone, P., Scarpa, P., Frackowiak, R.S., & Frith, C.D. (1994). The role of the right hemisphere in the interpretation of figurative aspects of language. A positron emission tomography activation study. *Brain*, 117, 1241-1253.
- Bryan, K. (1995). *The right hemisphere language battery* (2nd ed.). London: Whurr.
- Bryan, K.L., & Hale, J.B. (2001). Differential effects of left and right cerebral vascular accidents on language competency. *Journal of the International Neuropsychological Society*, 7, 655-664.
- Buchanan, T.W., Lutz, K., Mirzazade, S., Specht, K., Shah, N.J., Zilles, K., & Jaencke, L. (2000). Recognition of emotional prosody and verbal components of spoken language: an fMRI study. *Cognitive Brain Research*, 9, 227-238.
- Catafau, A.M., Lomena, F.J., Pavia, J., Parellada, E., Bernardo, M., Setoain, J., & Tolosa, E. (1996). Regional cerebral blood flow pattern in normal young and aged volunteers: a Tc-99m-HMPAO study. *European Journal of Nuclear Medicine*, 23, 1329-1337.
- Ferstl, E.C., Guthke, T., & von Cramon, D.Y. (2002). Text comprehension after brain injury: left prefrontal lesions affect inference processes. *Neuropsychology*, 16, 292-308.
- Gernsbacher, M.A., & Kaschak, M.P. (2003). Neuroimaging studies of language production and comprehension. *Annual Review of Psychology*, 54, 91-114.
- Goel, V., & Dolan, R.J. (2000). Anatomical segregation of component processes in an inductive inference task. *Journal of Cognitive Neuroscience*, 12, 110-119.

- Jodzio, K., Gąsecki, D., Drumm, D.A., Lass, P., & Nyka, W. (2003). Neuroanatomical correlates of the post-stroke aphasia studied with cerebral blood flow SPECT scanning. *Medical Science Monitor*, 9, MT32-41.
- Karow, C.M., Marquardt, T.P., & Marshall, R.C. (2001). Affective processing in left and right hemisphere brain-damaged subjects with and without subcortical involvement. *Aphasiology*, 15, 715-729.
- Kotz, S.A., Meyer, M., Alter, K., von Cramon, D.Y., & Friederici, A.D. (2003). On the lateralization of emotional prosody: an event-related functional MR investigation. *Brain and Language*, 86, 366-376.
- Lass, P. (1998). *Tomografia emisyjna pojedynczego fotonu jako metoda oceny zmian mózgowego przepływu krwi w wybranych układowych chorobach tkanki łącznej* (Single-photon emission computed tomography in the assessment of cerebral blood flow changes in selected collagen tissue diseases). Gdańsk: Via Medica.
- Łojek, E., Skotnicka, M., & Bryan, K.L. (2000a). A battery of neuropsychological tests for the assessment of language disorders in right brain damaged patients: preliminary results. *Polish Psychological Bulletin*, 31, 279-289.
- Łojek, E., Skotnicka, M., & Bryan, K.L. (2000b). Zestaw testów neuropsychologicznych do oceny zaburzeń językowych po uszkodzeniach prawej półkuli mózgu – wyniki badań wstępnych (Set of neuropsychological tests for the assessment of language disorders after damage to the right cerebral hemisphere – preliminary results). *Neurologia i Neurochirurgia Polska*, 34, 71-81.
- Myers, P.S. (1998). *Right hemisphere damage: disorders of communication and cognition*. San Diego: Singular Publishing Group.
- Myers, P.S. (2001). Toward a definition of RHD syndrome. *Aphasiology*, 15, 913-918.
- Nichelli, P., Grafman, J., Pietrini, P., Clark, K., Lee, K.Y., & Miletich, R. (1995). Where the brain appreciates the moral of a story. *Neuroreport*, 6, 2309-2313.
- Parsons, L.M., & Osherson, D. (2001). New evidence for distinct right and left brain systems for deductive versus probabilistic reasoning. *Cerebral Cortex*, 11, 954-965.
- Pell, M.D. (1996). On the receptive prosodic loss in Parkinson's disease. *Cortex*, 32, 693-704.
- Pell, M.D., & Baum, S.R. (1997). The ability to perceive and comprehend intonation in linguistic and affective contexts by brain-damaged adults. *Brain and Language*, 57, 80-99.
- Rinaldi, M.C., Marangolo, P., & Baldassarri, F. (2004). Metaphor comprehension in right brain-damaged patients with visuo-verbal and verbal material: a dissociation (re)considered. *Cortex*, 40, 479-490.
- Robertson, D.A., Gernsbacher, M.A., Guidotti, S.J., Robertson, R.W., Irwin, W., Mock, B.J., & Campana, M.E. (2000). Functional neuroanatomy of the cognitive process of mapping during discourse comprehension. *Psychological Science*, 11, 255-260.

- Seger, C.A., Desmond, J.E., Glover, G.H., & Gabrieli, J.D.E. (2000). Functional magnetic resonance imaging evidence for right-hemisphere involvement in processing unusual semantic relationships. *Neuropsychology*, 14, 361-369.
- Semmes, J. (1968). Hemispheric specialization: a possible clue to mechanism. *Neuropsychologia*, 6, 11-26.
- Shammi, P., & Stuss, D.T. (1999). Humor appreciation: a role of the right frontal lobe. *Brain*, 122, 657-666.
- St George, M., Kutas, M., & Sereno, M.I. (1999). Semantic integration in reading: engagement of the right hemisphere during discourse processing. *Brain*, 122, 1317-1325.
- Tompkins, C.A. (1995). *Right hemisphere communication disorders: theory and management*. San Diego: Singular Publishing Group.
- Turner, D.C., Aitken, M.R.F., Shanks, D.R., Sahakien, B.J., Robbins, T.W., Schwarzbauer, C., & Fletcher, P.C. (2004). The role of the lateral frontal cortex in casual associative learning: exploring preventative and super-learning. *Cerebral Cortex*, 14, 872-880.
- Ulatowska, H.K., Rymarczyk, K., & Kądziaława, D. (2003). Processing of proverbs by patients with right hemisphere damage. *Acta Neuropsychologica*, 1, 414-442.
- Van Lancker, D. (1990). The neurology of proverbs. *Behavioural Neurology*, 3, 169-187.